



¹⁸F-FDG Positron Emission Tomography/Computed Tomography in the Diagnosis and Post-Therapeutic Treatment in a Patient with an Early Stage of Retroperitoneal Fibrosis

Retroperitoneal Fibrozisi Erken Aşamada Olan Bir Hastada Tanı ve Tedavi Sonrası ¹⁸F-FDG Pozitron Emisyon Tomografisi / Bilgisayarlı Tomografi

Artor Niccoli Asabella¹, A. Nicoletti¹, C. Altini¹, A. Notaristefano¹, G. Lastilla², G. Rubini¹

¹University of Bari, Nuclear Medicine Unit – Di.M.I.M.P., Bari, Italy

²University of Bari, Anatomical Pathology Unit 2 – D.A.P.E.G., Bari, Italy

Abstract

Here, we report an experience about ¹⁸F-FDG-PET/CT in a patient with an early stage of Idiopathic Retroperitoneal Fibrosis (IRF). At the diagnosis Contrast Enhanced Computed Tomography (CE-CT) revealed periaortic solid tissue in the infrarenal section and locoregional lymph nodes; findings were interpreted as lymphomatous tissue. ¹⁸F-FDG-PET/CT showed elevated ¹⁸F-FDG uptake in the periaortic tissue but no uptake was detected in lymph nodes. The histologic examination showed recent-onset IRF. The patient began corticosteroid therapy. Nearly at the end of the therapy, CE-CT showed the enlargement of the fibrous tissue and ¹⁸F-FDG-PET/CT showed an increased ¹⁸F-FDG uptake in the aforesaid lesion and another area of uptake in the aortic wall. ¹⁸F-FDG-PET/CT can play an important role in the diagnosis of patients with an initial clinical suspicion of retroperitoneal fibrosis and in their management. Then the patient began a therapy with methotrexate and after six months we performed an ¹⁸F-FDG-PET/CT which didn't show ¹⁸F-FDG uptake.

Key words: ¹⁸F-FDG positron emission tomography/computed tomography, contrast enhancement computed tomography, idiopathic retroperitoneal fibrosis

Özet

Erken dönemde bir İdyopatik Retroperitoneal Fibrosis (IRF) hastasında yapılan ¹⁸F-FDG-PET/BT deneyimini sunduk. Tanı amaçlı Kontrastlı Bilgisayarlı Tomografide (CE-CT) infrarenal bölgede periaortik solid doku ve lokal-bölgesel lenf nodları görüldü ve lenfatik doku olarak yorumlandı. ¹⁸F-FDG-PET/BT periaortik dokuda artmış ¹⁸F-FDG tutulumu gösterdi ama lenf nodlarında hiç tutulum yoktu. Histolojik inceleme başlangıç aşamasında IRF olarak geldi. Tedavinin sonuna yakın, CE-CT fibröz dokuda artış ve ¹⁸F-FDG-PET/BT önceki bahsedilen lezyonda ve de aort duvarındaki başka bir lezyonda artmış ¹⁸F-FDG tutulumu görüldü. ¹⁸F-FDG-PET/BT, klinik olarak şüpheli bulunan retroperitoneal fibrosis vakalarının tanı ve yönlendirilmesinde önemli rol oynayabilir. Daha sonra hastaya methotrexate tedavisi başlandı ve altı ay sonra yapılan ¹⁸F-FDG-PET/BT de ¹⁸F-FDG tutulumu izlenmedi.

Anahtar kelimeler: ¹⁸F-FDG pozitron emisyon tomografisi/bilgisayarlı tomografi, kontrast bilgisayarlı tomografi, idiyopatik retroperitoneal fibrozis

Introduction

Idiopathic Retroperitoneal Fibrosis (IRF) is a rare disease (incidence between 40 and 60 years; M:F=2:1), defined as a connective-tissue disorder, characterized by the development of fibro-inflammatory tissue in retroperitoneum (1,2).

It is an insidious disease, which could be initially silent, or characterized by non-specific and/or systemic symptoms, sometimes associated with local ones due to the entrapment of retroperitoneal structures. It mostly manifests itself locally through abdominal and back pain (1,2).

Address for Correspondence: Artor Niccoli Asabella MD, University of Bari, Nuclear Medicine Unit – Di.M.I.M.P., Bari, Italy
Phone: +39 080 5592913 E-mail: a.niccoli@mednucl.uniba.it **Received:** 27.12.2011 **Accepted:** 26.11.2012

Here, we report an experience about ¹⁸F-FDG-Positron-Emission-Tomography/Computed-Tomography (¹⁸F-FDG-PET/CT) in the diagnosis and post-therapeutic evaluation in a patient with an early stage of IRF.

Case Report

A 43-year-old man came at our attention for cramp-like abdominal pain not responding to anti-inflammatory or anti-spastic therapies. Blood and urine tests were normal. One month later a contrast-enhancement computed-tomography (CE-CT) revealed the presence of periaortic solid tissue in the infrarenal section (thickness: 14 mm; longitudinal extension: 46 mm; 48-73 HU) and locoregional lymph nodes (Figure 1A).

These findings were interpreted as lymphomatous tissue. One week after CE-CT, blood test showed only increased erythrocyte sedimentation rate (ESR). One month after CE-CT, the patient underwent ¹⁸F-FDG-PET/CT in our Nuclear Medicine Unit, which showed elevated ¹⁸F-FDG uptake (Figure 1B-1C) in the periaortic tissue surrounding the descending aorta in front of the L3 vertebra (SUV max 4.6); no ¹⁸F-FDG uptake was detected in lymph nodes reported at the previous CE-CT (Figure 1B, red circle). After ¹⁸F-FDG-PET/CT the patient underwent laparoscopic biopsy; the histologic examination showed the presence of lobular lympho-plasmacellular aggregates and richly vascularized fibrous tissue, corresponding to recent-onset IRF. Then the patient began 9 months of corticosteroid therapy with Prednisone, with pain remission after the first month. After five months of therapy, the patient had a CE-CT (Figure 1D), which showed a size reduction of the solid tissue (thickness: 4 mm).

The inflammatory markers were normal. Nearly at the end of the therapy, corresponding with the lowering of prednisone dose, the patient reported the onset of abdominal pain. For this reason another CE-CT was performed which showed the enlargement of the fibrous tissue (thickness: 8 mm; longitudinal extension: 49 mm, 32-61 HU). A second ¹⁸F-FDG-PET/CT showed increased ¹⁸F-FDG uptake, corresponding to the aforesaid lesion

(SUV_{max} 7.3). Another area of ¹⁸F-FDG uptake (Figure 1E-1F, green arrow) was observed on the right-posterior-lateral aortic wall, at L2 vertebra level (SUV max 5.1). Therefore, according to ¹⁸F-FDG-PET/CT findings, clinicians began a new regimen of prednisone and methotrexate (MTX).

After six months we performed an ¹⁸F-FDG-PET/CT which didn't show any area of pathological ¹⁸F-FDG uptake, confirming the therapy's outcome and then the end of the MTX use (Figure 2).

Literature Review and Discussion

Macroscopically IRF appears as a fibrous mass, localized between the origin of the renal arteries and the bifurcation of the common iliac at the level of the L4-L5 vertebra (3). Histologically, in the early stages, the tissue is richly vascularized with chronic active inflammation (1, 3); in advanced stages becomes less vascularized and richer in dense collagen fibers (1, 4). CE-CT and magnetic resonance are the imaging techniques of choice for diagnosis and

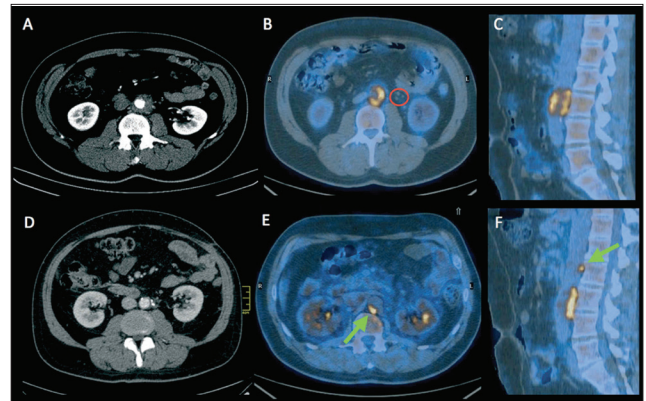


Figure 1. (A) Transaxial CE-CT image performed at diagnosis, showing periaortic solid tissue and locoregional lymph nodes. (B) Transaxial and (C) Sagittal ¹⁸F-FDG-PET/CT fused image performed at diagnosis, showing ¹⁸F-FDG uptake in the periaortic tissue; no ¹⁸F-FDG uptake in lymph nodes reported at CE-CT (red circle). (D) Transaxial CE-CT image performed during corticosteroid therapy, showing size reduction of the solid tissue. (E) Transaxial and (F) sagittal ¹⁸F-FDG-PET/CT fused image performed one month after the end of therapy, showing.

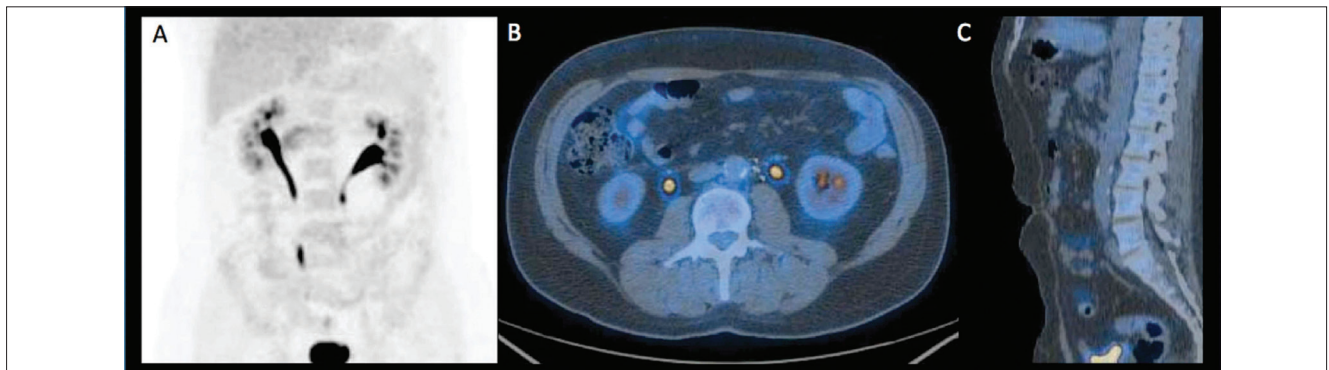


Figure 2. (A) MIP, (B) transaxial and (C) sagittal ¹⁸F-FDG-PET/CT fused image performed after 6 months from the beginning of therapy with prednisone and methotrexate which didn't show ¹⁸F-FDG uptake.

quantification of IRF. CE-CT shows a variable degree of enhancement: intense in the early and acute stages of the disease, minimal in advanced stages. ¹⁸F-FDG-PET/CT is used primarily to assess the metabolic activity of the mass. It is useful for identification of aortitis and periaortitis in the acute phase, evaluation of IRF after treatment and in cases of relapse (5,6). The first prospective study in 26 patients evaluated the potential role of ¹⁸F-FDG-PET/CT in assessing disease activity. It showed that positive ¹⁸F-FDG-PET/CT correlates with C-reactive protein (CRP) level and with lesion size. Visual PET score decreased after tamoxifen therapy and correlates with Erythrocyte Sedimentation Rate (ESR) reduction, but not with CT mass regression. The authors concluded that ¹⁸F-FDG-PET/CT is valuable in detecting disease activity (presumed IRF or suspected recurrence), particularly in the absence of symptoms and acute phase reactant increase (7).

Definitive diagnosis requires biopsy (8) and histological examination. In medical therapy, steroids play a leading role (9). Methotrexate, azathioprine and mycophenolate are usually reserved for patients who do not benefit from corticosteroid treatments (10). Tamoxifen can also be used, due to its anti-inflammatory and anti-fibrosis action, but corticosteroid therapy is better than tamoxifen in maintenance of remission in patients with idiopathic retroperitoneal fibrosis, and induces a greater shrinkage of the retroperitoneal mass than tamoxifen does (11).

The peculiarity of this case is that our patient showed abdominal pain in an early phase because of the unusual higher location of the disease (at a L3 vertebra level, rich of nerve endings).

In laboratory tests, the most important anomalies that occur are: increased ESR, CRP, the alpha-2-globulin (4). In our patient, CRP values were always within normal range, on the contrary, ESR values were variously amended in agreement with morphological data provided by CE-CT.

¹⁸F-FDG-PET/CT led the initial differential diagnosis (lymphoma? Retroperitoneal fibrosis?) documenting the absence of glucose hyper-metabolism in the lymph nodes detected by CE-CT; it ruled out the presence of an extra-peritoneal localization of the disease and identified the most suitable site for biopsy. We did not perform an ¹⁸F-FDG-PET/CT during the therapy because the patient was asymptomatic, the inflammatory markers were normal and CE-CT showed lesion size reduction, a clear proof of a good response to therapy. ¹⁸F-FDG-PET/CT is able to identify with higher sensitivity compared to CT, the persistence of inflammation in the residual tissue after therapy (12,13)

In our patient, one month after the end of the therapy, ¹⁸F-FDG-PET/CT showed a higher ¹⁸F-FDG uptake than the previous ¹⁸F-FDG-PET/CT, despite ESR was altered still below the threshold of diagnosis; it also showed a new site of inflammation of the aortic vessel wall, not shown by the CE-CT.

It was found interesting that CE-CT performed one month after the end of the corticosteroid therapy, compared to the CE-CT performed at the diagnosis, showed a size reduction by 43% and a CE reduction from 48-73 HU to

32-61 HU, while ¹⁸F-FDG-PET/CT, performed at the end of corticosteroid therapy, compared with that performed at the diagnosis, showed an increase of ¹⁸F-FDG uptake by 51%. We have hypothesized that metabolic changes that occurs in the recurrence precede the morpho-structural ones and justify the increment of ¹⁸F-FDG uptake and the absence of CE-CT increase at the same sites.

This metabolic evidence was important in the choice of the new therapeutic strategy.

¹⁸F-FDG-PET/CT can play an important role in the diagnosis of patients with an initial clinical suspicion of retroperitoneal fibrosis, providing useful data for the differential diagnosis from other retroperitoneal diseases. It is also useful in cases of exacerbation and progression of the disease, highlighting new foci of inflammation, not documented at morphological imaging (CE-CT), helping the choice of a valid therapeutic strategy and monitoring the disease free survival.

References

1. Vivas I, Nicolás AI, Velázquez P, Elduayen B, Fernández-Villa T, Martínez-Cuesta A. Retroperitoneal fibrosis: typical and atypical manifestations. *Br J Radiol* 2000;73:214-222.
2. Drieskens O, Blockmans D, Van den Bruel A, Mortelmans L. Riedel's thyroiditis and retroperitoneal fibrosis in multifocal fibrosclerosis: positron emission tomographic findings. *Clin Nucl Med* 2002;27:413-415.
3. Katz R, Golijanin D, Pode D, Shapiro A. Primary and postoperative retroperitoneal fibrosis-experience with 18 cases. *Urology* 2002;60:780-783.
4. Vaglio A, Corradi D, Manenti L, Ferretti S, Garini G, Buzio C. Evidence of autoimmunity in chronic periaortitis: a prospective study. *Am J Med* 2003;114:454-462.
5. Schirmer M, Calamia KT, Wenger M, Klauser A, Salvarani C, Moncayo R. ¹⁸F-fluorodeoxyglucose-positron emission tomography: a new explorative perspective. *Exp Gerontol* 2003;38:463-470.
6. Nabi HA, Zubeldia JM. Clinical applications of (18)F-FDG in oncology. *J Nucl Med Technol* 2002;30:3-9.
7. Jansen I, Hendriksz TR, Han SH, Huiskes AW, van Bommel EF. (18)F-fluorodeoxyglucose positron emission tomography (FDG-PET) for monitoring disease activity and treatment response in idiopathic retroperitoneal fibrosis. *Eur J Int Med* 2010;21:216-221.
8. Monev S. Idiopathic retroperitoneal fibrosis: prompt diagnosis preserves organ function. *Cleve Clin J Med* 2002;69:160-166.
9. Feild C, Arnold W, Gloster ES, Sharp G, Redman J. Steroid therapy as treatment for idiopathic fibrosis of the retroperitoneum and mediastinum. *Pediatrics* 1986;78:936-938.
10. Grotz W, von Zedtwitz I, Andre M, Schollmeyer P. Treatment of retroperitoneal fibrosis by mycophenolate mofetil and corticosteroids. *Lancet* 1998;352:1195.
11. Vaglio A, Palmisano A, Alberici F, Maggiore U, Ferretti S, Cobelli R, Ferrozzi F, Corradi D, Salvarani C, Buzio C. Prednisone versus tamoxifen in patients with idiopathic retroperitoneal fibrosis: an open-label randomised controlled trial. *Lancet* 2011;378:338-346.
12. Vaglio A, Versari A, Fraternali A, Ferrozzi F, Salvarani C, Buzio C. (18)F-fluorodeoxyglucose positron emission tomography in the diagnosis and followup of idiopathic retroperitoneal fibrosis. *Arthritis Care & Research* 2005;15:122-125.
13. Lee YK, Seo JB, Kim SS, Lim TH. Thoracic periaortic fibrosis mimicking malignant tumor: CT and ¹⁸F-FDG PET findings. *AJR Am J Roentgenol* 2007;188:345-347.